


RESEARCH FRONTIERS

Studying New Stem Cell Therapies for Vision Recovery

The National Eye Institute (NEI) has awarded researchers at Icahn School of Medicine at Mount Sinai a five-year grant to support an effort to recreate a patient's ocular stem cells and restore vision in those blinded by corneal disease.

Specifically, the grant will allow Mount Sinai researchers to recreate a patient's own stem cells by taking mature cells, such as eyelid or oral skin cells, and coaxing them backward along the development pathways to become eye-specific stem cells again, and serving ultimately as needed replacements



▲ Left to right: Icahn School of Medicine at Mount Sinai investigators J. Mario Wolosin, PhD, Ihor Lemischka, PhD, and Albert Y. Wu, MD, PhD

for damaged cells in the cornea, says Principal Investigator Albert Y. Wu, MD, PhD, Assistant Professor, Ophthalmology, Director of the Ophthalmic Plastic and Reconstructive Surgery, Stem Cell and

Regenerative Medicine Laboratory, and a member of The Black Family Stem Cell Institute at the Icahn School of Medicine.

The funding will also allow investigators to research the most viable stem cell sources, explore the molecular pathways involved in ocular and orbital development, and develop cutting-edge biomaterials to engraft a patient's own stem cells and restore vision. Ihor Lemischka, PhD, Lillian and Henry M. Stratton Professorial Chair of Gene and Cell Medicine, and J. Mario Wolosin, PhD, Professor of Ophthalmology, are co-investigators with Dr. Wu.

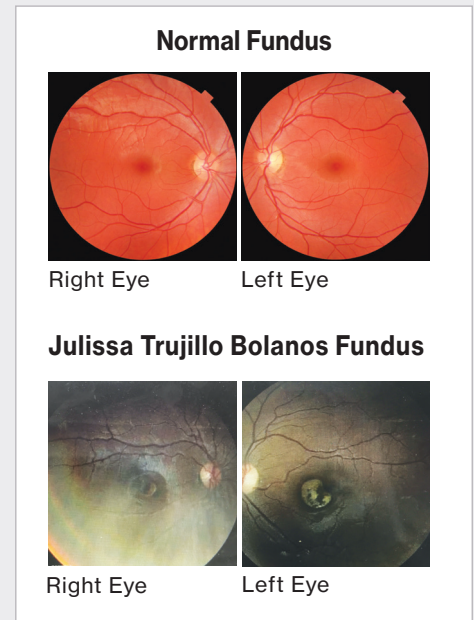
Treating the Ophthalmic Complications of Cobalamin C Deficiency

In 2012, three-year-old Julissa Trujillo Bolanos presented to the Ophthalmology Faculty Practice at The Mount Sinai Hospital as a timid, difficult-to-examine toddler with low vision, nystagmus, and a large angle left exotropia.

Julissa’s medical history is notable for Cobalamin C deficiency, a rare inherited disease characterized by hypotonia, lethargy, mental retardation, seizures, vision problems, and blood-related problems. She was referred for evaluation by George A. Diaz, MD, Chief, Division of Medical Genetics, Department of Genetics and Genomic Sciences, Icahn School of Medicine at Mount Sinai. Dr. Diaz is also Associate Director of the Program for Inherited Metabolic Diseases, one of the largest metabolic disease treatment programs in the country. Dr. Diaz and his team were managing the patient’s underlying metabolic condition and sought out an ophthalmology consultation with Tamiesha Frempong, MD, Assistant Professor of Ophthalmology and Pediatrics, Icahn School of Medicine at Mount Sinai.

Ocular findings in persons with Cobalamin C deficiency are variable. Optic atrophy, peripheral retinopathy, and central macular atrophy with a bull’s eye pattern or a normal fundus appearance are among the possible findings. Unfortunately, Julissa’s poor vision was immediately evident by her nystagmus and prominent strabismus. Her dilated fundus findings, captured by the photographs at right, revealed bilateral macular atrophic lesions in a bull’s eye pattern with the left macular defect greater than the right.

Despite a guarded visual prognosis given her low vision at presentation and anatomic defects, the Mount Sinai clinical team asked her parents to patch the right eye a few hours a day. After a few months, her nystagmus and prominent strabismus persisted; however, she started to fixate with the left eye if the right eye was covered. As a result, her parents and the care team, led by Dr. Frempong, decided to proceed with strabismus surgery of the left eye. Over the course of the last three years, with the



help of continued amblyopia management including glasses, Julissa’s nystagmus resolved, her eyes are straight and her best-corrected visual acuity in each eye has remarkably improved to 20/30.

Adaptive Optics: From the Lab to the Clinic

Richard Rosen, MD, Director of Ophthalmology Research and Director of the Retina Service at New York Eye and Ear Infirmary of Mount Sinai, and a team of researchers in the Shelley and Steven Einhorn Clinical Research Center, are pioneering imaging technology through the NYEE Adaptive Optics Laboratory by incorporating adaptive optics (AO) technology with fluorescein angiography.

AO was originally developed by astronomers to view objects in space without distortions caused by the atmosphere, whereas fluorescein angiography involves injection of dye into a patient’s arm, which is then recorded digitally as it moves through the bloodstream into the eye.

Dr. Rosen says AO combined with fluorescein angiography will make it possible for physicians to study how diseases unfold on a cellular level so they can devise more effective treatments. “With

this approach, we can appreciate very early changes and potentially intervene with treatment when the disease could be at a reversible stage,” he explains. “It can take over ten years for some patients to lose vision, with no visible changes seen with currently available imaging modalities. With AO, we can detect minute changes much earlier and hope to improve the standard of care and prevent blindness.”

Diabetic retinopathy, for example, is typically diagnosed and treated with laser surgery or intraocular injections at a later stage, says Dr. Rosen. If the disease were detected earlier, physicians might be able to prevent vision loss with milder, less-invasive treatments.

In a recent study involving 10 healthy volunteers that was funded, in part, by the National Eye Institute, Dr. Rosen and researchers at the Medical College of Wisconsin found that combining AO technology and an oral form of the dye mixed with orange juice

New York Eye and Ear Infirmary Sees Excellence In Union With Mount Sinai Health System


When two highly regarded organizations share a commitment to outstanding patient care, basic and translational research, and the education of future practitioners, the foundation exists for a superior collaboration. I am pleased to report that, two years on, the unification of Mount Sinai Health System and New York Eye and Ear Infirmary of Mount Sinai, the nation's first specialty hospital, is proving itself such a collaboration in the field of Ophthalmology.

Drawing on both common and unique strengths, the Department of Ophthalmology at the Icahn School of Medicine at Mount Sinai has created a storehouse of pooled service and learning, with more than 60 full-time faculty members across the health system and one of the largest ophthalmology graduate medical education programs in the United States, comprising the residency and fellowship training programs at NYEE and The Mount Sinai Hospital. A large, diverse volume of patients (approximately a quarter-million outpatient visits and more than 25,000 surgical procedures annually at NYEE alone), state-of-the-art technology, and academic expertise in virtually every

eye disease offer the promise of breakthrough results, in the lab and at the bedside.

Through our ongoing integration, the Department has identified several priority areas for translational research, including ocular stem cell/regenerative cell biology, glaucoma and neuroscience, ocular imaging and functional correlation, and genetics/genomics of the eye.

In terms of clinical applications and utility to the specialty, we are at the beginning stages of creating an eye and tissue repository that will marshal the diverse ocular pathogens that are seen and treated in our distinctly unique urban academic centers. We believe this centralized, shared resource will allow advanced diagnostic and therapeutic strategies to be developed by our surgeons, clinicians, and researchers, as well as facilitate extramural research across the country. We are also planning the formation of an ophthalmology telemedicine



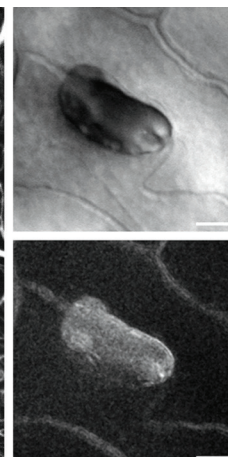
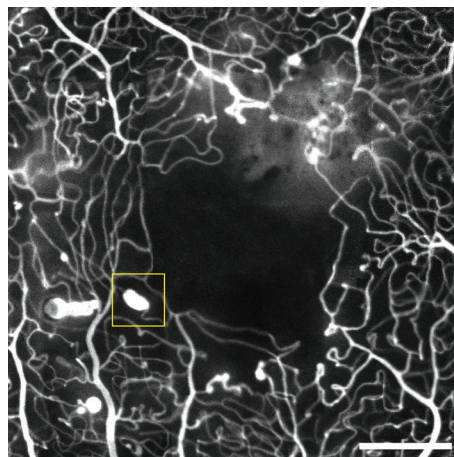
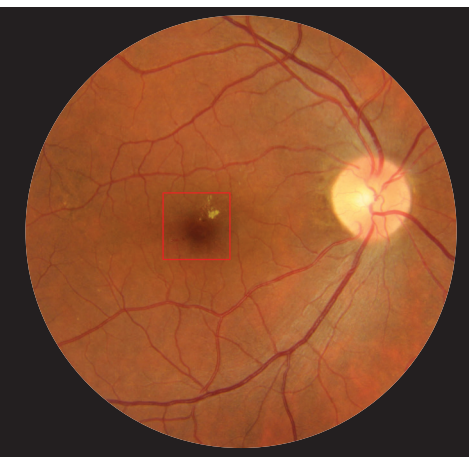▲ James C. Tsai, MD, MBA

program to help enhance access to superior care in all phases of the care process: diagnosis, therapy, follow-up, and education.

The future is certainly promising. As always, the patient will come first. Everything we do is driven by a dedication to delivering world-class, compassionate, convenient care. To that end,

our union goes a step further with plans to expand NYEE's clinical excellence across the entire Mount Sinai Health System, making patient care easier to access at our seven hospital campuses, and across the New York region.

Over the next year, we will continue to use synergies between the two entities to create even more exceptional clinical care for our unparalleled number and breadth of patients, expand our state-of-the-art technology for disease characterization, and share our academic expertise in virtually every eye disease.



◀ Images of the right eye of a 49-year-old patient with hypertensive retinopathy. Left panel: Overview fundus picture. Red box indicates the region imaged with high resolution fluorescein angiography AOSLO as shown on the middle panel. Middle panel: Fluorescein angiography AOSLO shows microaneurysms with different morphologies. Scale bar = 100µm. Right panel: Structural AOSLO and dyeless perfusion images of the microaneurysm located inside the yellow box on the middle panel. Scale bars = 25µm.

provided a stronger, longer-lasting signal than the dye administered intravenously. It was tolerated by all of the volunteers, whereas one volunteer who received an intravenous injection became nauseous.

Going forward, Dr. Rosen says one of the biggest challenges will be to make AO technology accessible to all ophthalmologists. Once the technology becomes more cost-effective, it can be incorporated into clinical trials and patient care.

People With AIDS Have Much Higher Risk of Macular Degeneration, Mount Sinai Researchers Report

Patients with acquired immunodeficiency syndrome (AIDS) have a four-fold increase in their risk of developing intermediate-stage age-related macular degeneration (AMD) compared to people of the same age who are not infected with HIV, according to a new study led by the Studies of the Ocular Complications of AIDS Research Group. The results of the research, the Longitudinal Study of the Ocular Complications of AIDS (LSOCA), were presented at the ARVO 2015 Annual Meeting in May by Douglas A. Jabs, MD, MBA, Professor of Ophthalmology, and Medicine, at the Icahn School of Medicine at Mount Sinai.



▲ Douglas A. Jabs, MD, MBA

The study, funded by the National Eye Institute, also determined that the increased prevalence of AMD in the LSOCA cohort was not related to any drug or class of drugs used to treat HIV

infection. Rather, researchers point out that antiretroviral-treated, immune-restored, HIV-infected patients do not have normal immune systems; instead and on average they have immunologic changes similar to those seen in patients who are not infected who are older than 70 years of age, a phenomenon termed “immunosenescence.”

The Ocular Complications of AIDS Research Group notes that further exploration of these findings may provide the opportunity to better understand the roles of immunosenescence and systemic inflammation in the development of AMD,

which in turn could lead new treatments. The results also add to the growing body of research suggesting that antiretroviral therapy-treated, immunorestored, HIV-infected persons may experience accelerated and accentuated aging.

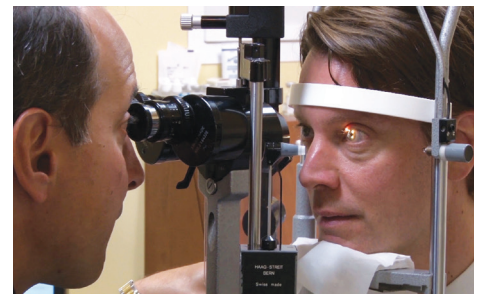NYEE’s Eye Trauma Service Advances Ocular Surgery

Eye injury is a leading cause of monocular blindness in the United States. Just over 1 million people in the United States, and 42 million around the world are blind from trauma. Causes of eye injuries vary and are most often related to injury from blunt objects (31 percent) or sharp objects (18 percent).

New York Eye and Ear Infirmary of Mount Sinai is a national eye trauma center and the only service in the New York City metropolitan region with expertise in treating patients with ocular trauma. The Ocular Trauma Service is an integrated multi-specialty service with more than 25 board certified eye surgeons representing NYEE’s Anterior Segment, Retina, and Oculoplastic Services. Coverage is 24-hours a day, with a triage officer represented by the Senior House Staff. Patients are referred from the New York region, as well as from around the United States, for primary and secondary

repair of complex ocular injuries. In 2014, the program saw more than 2,000 patients, with most patients being referred from other institutions and community practices for the NYEE’s expertise and specialized equipment.

One such patient, John McKnight, MD, a primary care physician practicing in New York, was referred to the NYEE Ocular Trauma Service from the ophthalmologist on call at his own hospital. After an accident at home left him with a ruptured globe, he was immediately seen and treated by an NYEE program resident and received follow-up care by Ronald Gentile, MD, Professor of Ophthalmology, Icahn School of Medicine at Mount Sinai, and Chief, Ocular Trauma Service. Dr. McKnight underwent surgery to repair a rupture of the eye wall, which covered approximately 30 percent of the entire globe. As a result of the series of procedures and with the use of a contact lens, Dr. McKnight’s recovery



▲ Ronald Gentile, MD (left) examines eye trauma patient John McKnight, MD

has exceeded expectations, achieving better than 20/40 vision in his traumatized eye. Based on a standard ocular trauma prognostic scale, Dr. McKnight’s outcome was in the top one percent of similarly traumatized eyes.

Cases like Dr. McKnight’s have allowed NYEE physicians to advance the field of ocular trauma and develop novel surgical techniques that have been disseminated around the world. To further the impact of the program’s experience, NYEE will be releasing an Eye Trauma CME Webinar supported by Carl Zeiss Meditec within the next year. This series will include talks on both orbital and ocular trauma.